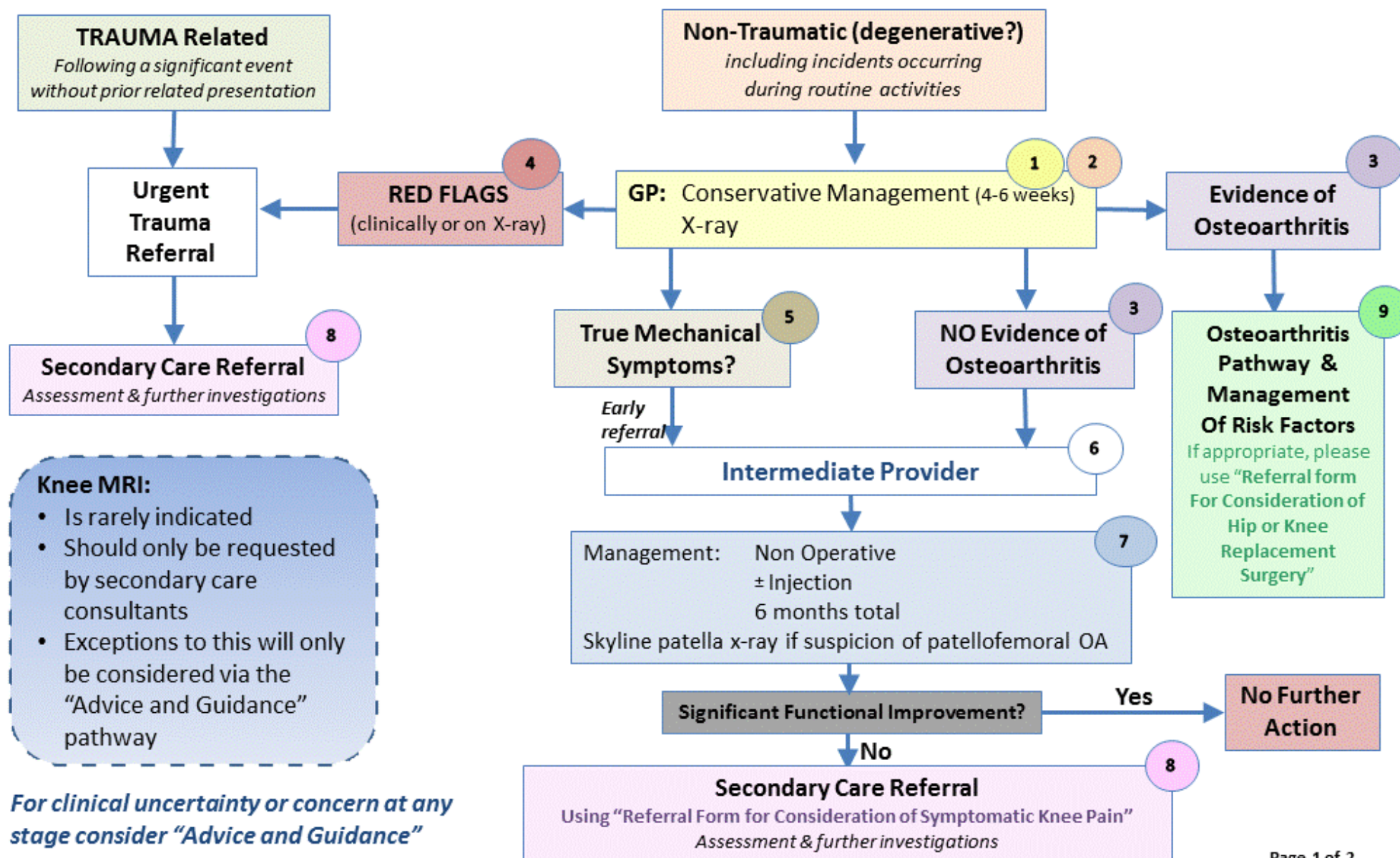


Symptomatic Knee Pain Pathway

Knee swelling - Point tenderness - Jointline



Symptomatic Knee Pain Pathway Definitions

May 2018

1

GP Conservative Treatment (4 to 6 weeks):

- Pain Management (NSAID/paracetamol)
- Home exercises
- Risk Factor Management (see 9)
- Physiotherapy
- Intra-articular injection

2

X-rays:

- To exclude non-meniscus related disease
- Require anteroposterior weight bearing (*with ? OA on order form*), lateral
- Skyline patella x-rays may only be ordered by MSK specialists in intermediate and secondary care

3

Evidence Indicative of Osteoarthritis (OA):

Radiographic reporting features indicative of OA (including osteophytes, joint space narrowing, degenerative joint disease (DJD))

Age 45 years of age or more with symptoms & signs clearly suggesting OA (NICE 2015):

- Affected joints are painful when used (+/- pain at rest, crepitus, limited range movement)
- Affected joints become stiff after resting

4

RED FLAGS (clinically or on X-ray):

- ❖ Suspicion of septic arthritis, osteonecrosis or slipped capital femoral epiphysis
- ❖ Fracture cannot be excluded
- ❖ Severe soft tissue injury with gross instability

5

True Mechanical Symptoms:

- ❖ Knee giving way with pain daily or near daily for at least 1 month, OR
- ❖ Episodes of locking in FLEXION (true locking)

6

Intermediate Care Provider:

Redditch & Bromsgrove CCG – Community Based Physiotherapy Service

South Worcestershire CCG – MSK Extended Scope Physiotherapist (WH&CT)

Wyre Forest CCG – Practice Based Extended Scope Physiotherapist

7

Non-Operative Management:

3 phased programme, in accordance with ESSKA guidance, over 6 months aiming to:

- control the pain and swelling
- restore the range of motion (ROM)
- restore or maintain isolated muscle function and
- optimize lower extremity neuromuscular coordination and muscle strength

8

Indications for Arthroscopic Partial Meniscectomy (APM):

- Acute traumatic (non-degenerative) tears
- Degenerative meniscal tear with:
 - Meniscal fragment in tibial gutter (\pm adjacent bone oedema)
 - Parameniscal cyst
 - True mechanical symptoms

Indications for Chondroplasty:

- Patellofemoral osteoarthritis with recurrent swelling

9

Lifestyle Advice/Risk Factors:

- ❖ Maintain a healthy weight; excess weight can increase biomechanical load and may worsen the condition
- ❖ Maintain a level of regular activity to maintain good joint function; plan increases in activity methodically
- ❖ Quit smoking; there is an established link between smoking and musculoskeletal pain

Worcestershire Clinical Commissioning Policy Collaborative